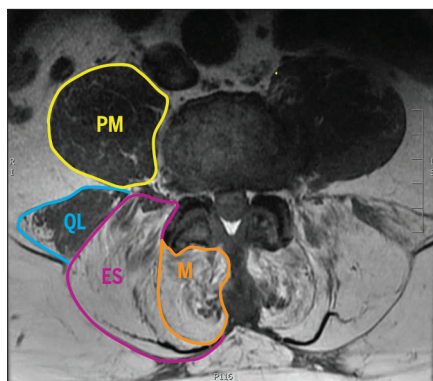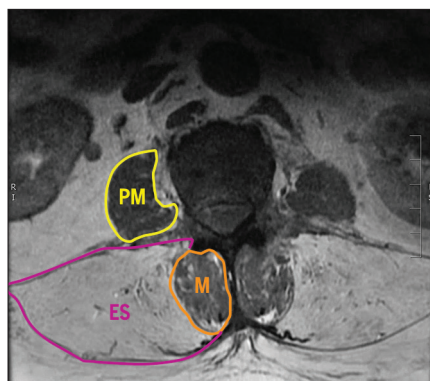
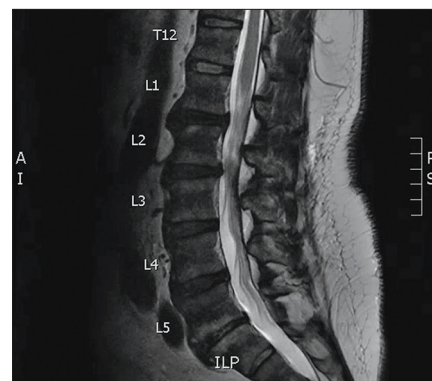


**FIGURE 1.** A T1-weighted, axial magnetic resonance image of the lumbar paraspinal musculature at the L4-L5 level indicating fatty replacement of the whole paraspinal muscle compartment, with preservation of the PM and some preservation of the right QL. Abbreviations: ES, erector spinae; M, multifidus; PM, psoas major; QL, quadratus lumborum.



**FIGURE 2.** A T1-weighted, axial magnetic resonance image of the lumbar paraspinal musculature at the L2-L3 level indicating preservation of the M and PM muscles and complete fatty replacement of the ES muscles within the epimysium. Abbreviations: ES, erector spinae; M, multifidus; PM, psoas major.



**FIGURE 3.** A T2-weighted, midline, sagittal magnetic resonance image of the lumbar spine demonstrating relatively normal spinal alignment and no evidence of major cord compression from soft tissue or bony structures.

## Selective Fatty Replacement of Paraspinal Muscles in Facioscapulohumeral Muscular Dystrophy

**BAHAR SHAHIDI**, PT, PhD, *Department of Orthopaedic Surgery, University of California, San Diego, San Diego, CA.*

**SAMUEL R. WARD**, PT, PhD, *Department of Orthopaedic Surgery and Department of Radiology, University of California, San Diego, San Diego, CA.*

**A** 65-YEAR-OLD MAN PRESENTED TO his physician 3 months after a fall with a complaint of new-onset low back pain, bilateral foot numbness, and left lower extremity radicular symptoms with foot drop. The patient had a history of facioscapulohumeral muscular dystrophy. He subsequently underwent magnetic resonance imaging of the lumbar spine and was referred to physical therapy.

The patient's magnetic resonance images revealed complete fatty replacement of the erector spinae musculature throughout the lumbar spine (FIGURE 1). Interestingly, preservation of the lumbar multifidus muscles above the L4 level was

observed, which has not previously been reported in patients with this condition (FIGURE 2). Psoas major and quadratus lumborum muscles were similarly preserved throughout. The patient's lower extremity symptoms were consistent with left L5-S1 radiculopathy, and the magnetic resonance images indicated mild to moderate central canal stenosis at L2-L3 (FIGURE 3) with severe bilateral L5-S1 foraminal narrowing.

The radiographic and clinical presentation of facioscapulohumeral muscular dystrophy typically includes upper extremity functional loss and axial muscle degeneration, which commonly manifests as bilateral and symmetrical atrophy and an increased proportion of fat within the

muscle boundaries of the paraspinal musculature, ranging between 30% and 40%.<sup>1,2</sup> The magnitude of fatty infiltration in this patient's paraspinal muscle compartment was quantified to be over 80%, which has not been previously reported in the literature. Additionally, the selective fatty infiltration of the erector spinae muscle group with preservation of the multifidus, psoas major, and quadratus lumborum in the upper lumbar spine has not been previously described and may provide physical therapists with a viable target (the multifidus) for focused core-strengthening exercises in this patient population. ● *J Orthop Sports Phys Ther* 2019;49(6):483. doi:10.2519/jospt.2019.8815

### References

- Andersen G, Dahlqvist JR, Vissing CR, Heje K, Thomsen C, Vissing J. MRI as outcome measure in facioscapulohumeral muscular dystrophy: 1-year follow-up of 45 patients. *J Neurol*. 2017;264:438-447. <https://doi.org/10.1007/s00415-016-8361-3>
- Dahlqvist JR, Vissing CR, Thomsen C, Vissing J. Severe paraspinal muscle involvement in facioscapulohumeral muscular dystrophy. *Neurology*. 2014;83:1178-1183. <https://doi.org/10.1212/WNL.0000000000000828>

This imaging report was supported by grant R01HD088437 from the National Institutes of Health, awarded to Dr Ward, and grant R03HD094598 from the National Institutes of Health, awarded to Dr Shahidi.